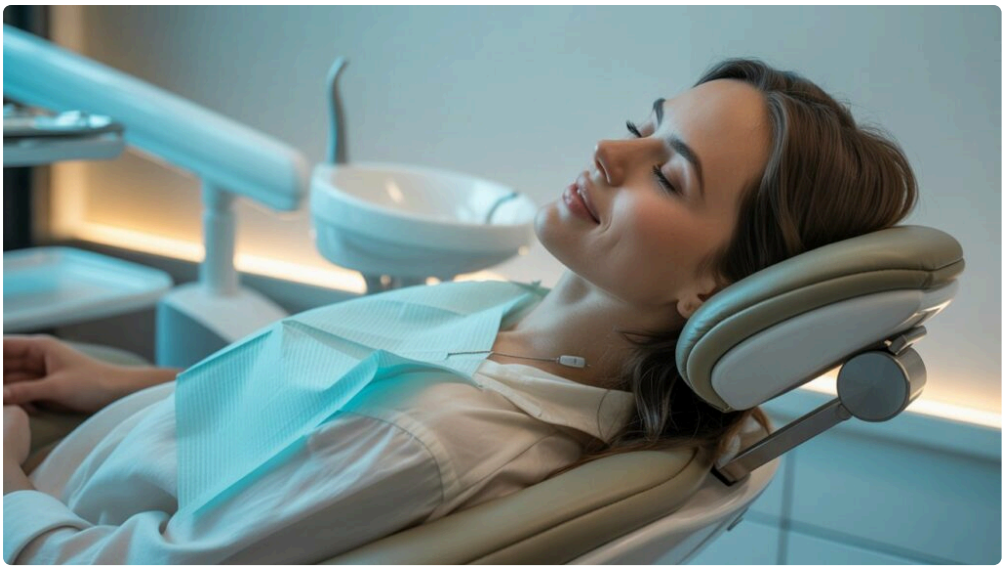

Few moments rattle a parent faster than seeing a child cry with a bloody mouth and a tooth in hand. It often happens in ordinary places, a driveway, a trampoline park, a soccer field, a classroom. One second everything is normal, the next you are trying to decide whether to call the dentist, head to urgent care, or simply offer ice cream and watch for swelling. The hardest part is that the right response depends heavily on one question: was it a baby tooth or a permanent tooth?

That distinction changes almost everything. Baby teeth and permanent teeth do not play by the same rules in a dental emergency. What helps one can seriously harm the other. I have seen parents do exactly what they thought was helpful, only to learn later that the injured tooth should never have been put back, or that time mattered far more than they realized. The good news is that a few clear principles can guide you in a stressful moment.

Why the type of tooth matters so much

A baby tooth is temporary, but it is not disposable. These teeth hold space for adult teeth, support speech development, help children chew comfortably, and influence jaw growth. Still, when a baby tooth is injured, the

dentist is often thinking not only about that tooth, but also about the ***Dental Emergency*** permanent tooth developing directly beneath it.

A permanent tooth has a different priority. Once it erupts, the goal is to preserve it for life. If it is knocked out, cracked, or displaced, fast action may determine whether the tooth survives. The supporting tissues around a permanent tooth, especially the periodontal ligament on the root surface, are delicate. They do not tolerate drying out or rough handling well. Minutes matter.

This is why parents hear two very different instructions in similar-looking accidents. A knocked-out permanent tooth may need immediate reimplantation or transport in milk. A knocked-out baby tooth should not be pushed back into the socket. One is a race to save the tooth. The other is a situation where protecting the developing adult tooth takes priority.

The first question to ask: is this a baby tooth or a permanent tooth?

That sounds simple until you are staring at a frightened seven-year-old who has blood on their shirt. Age helps, but it is not foolproof. Most children begin losing baby teeth around age six, and many have a mix of baby and permanent teeth for years. Front permanent incisors usually appear between ages six and eight. By age nine, many children still have baby molars even though their front permanent teeth have been in for a while.

There are a few clues. Baby teeth are usually smaller, whiter, and have shorter roots once they are naturally ready to fall out. Permanent teeth often look slightly yellower and larger, with more pronounced edges when newly erupted. If the lost tooth came from the upper or lower front and your child is under five, it was almost certainly a baby tooth. If your child is eight and loses a front tooth in a crash, that may very well be permanent.

If you cannot tell, treat it as urgent and call a dentist immediately. Sending a photo can help many dental offices guide you before you arrive.

When a baby tooth is injured

Parents often underestimate baby tooth injuries because the tooth was “going to fall out anyway.” Sometimes that is true, but often the impact involves the gums, bone, lips, or the unseen permanent tooth bud underneath. The child may also have pain that builds over several hours rather than instantly.

A baby tooth can be chipped, pushed inward, loosened, driven upward into the gum, or knocked out completely. Of those scenarios, the one that surprises parents most is intrusion, where the tooth appears shorter or vanishes partially into the gum after a fall. In young children, this can happen when they hit a coffee table, bathtub edge, or playground equipment. It looks alarming because it is alarming. The tooth may have been pushed toward the developing permanent tooth. That needs prompt evaluation.

A loose baby tooth after trauma is not always an emergency in the middle of the night, but it should be assessed soon, especially if the child cannot bite normally or the tooth is dramatically displaced. Some mildly mobile baby teeth can be observed. Others need smoothing, repositioning, or extraction if they interfere with the bite or pose an aspiration risk.

If a baby tooth is knocked out, do not put it back in. That is one of the most important distinctions in pediatric dental trauma. Reimplanting a baby tooth can injure the permanent tooth developing below. Instead, control bleeding with gentle pressure using clean gauze, keep the child calm, and arrange dental follow-up. The socket often looks dramatic, but bleeding usually slows within a reasonable period if steady pressure is applied.

When a permanent tooth is injured

The tone changes completely when the lost tooth is permanent. With permanent teeth, especially front teeth, preserving the tooth is often possible if action is quick and correct. The classic dental emergency is a permanent tooth that has been knocked out entirely, root and all. In that situation, the tooth should be handled only by the crown, the part normally visible in the mouth. Do not scrub the root. If the tooth is dirty, it can be rinsed briefly with milk or saline, and sometimes clean water if nothing else is available, but rough cleaning reduces the chance of success.

If the child is old enough and cooperative, placing the tooth back into the socket right away can be the best option. That said, many parents are understandably hesitant, and not every child is a good candidate for that in the moment. If you cannot reinsert it, the tooth should be kept moist, ideally in cold milk or a tooth preservation solution if available. A child old enough not to swallow the tooth may sometimes keep it tucked in the inside of the cheek, but milk is usually safer and more practical.

A permanent tooth that is cracked or chipped also deserves attention, though the urgency varies. A tiny edge chip may wait for an appointment within a day or two. A larger fracture with sensitivity to air, bleeding from the tooth itself, or visible pink tissue is more urgent. A tooth that has shifted out of position, feels suddenly “high” when biting, or causes the child to avoid closing their mouth should be seen promptly. These are signs that the supporting structures may be damaged.

What to do in the first 30 minutes

In the first half hour, your job is not to solve the entire problem. It is to keep the child safe, reduce avoidable damage, and get to the right professional.

- Stay calm, check for head injury, and make sure the child is breathing normally and acting appropriately.
- Control bleeding with clean gauze or a clean cloth, using gentle but steady pressure.
- Find the tooth or tooth fragment, and identify whether it appears to be baby or permanent.
- If it is a permanent tooth that is fully knocked out, handle it by the crown only and keep it moist in milk or saline, or reinsert it if advised and feasible.
- Call a dentist immediately, and go to urgent care or the emergency room if there is facial trauma, loss of consciousness, vomiting, severe swelling, or concern for a jaw fracture.

That sequence covers the majority of home and playground accidents. It also prevents the two mistakes that cause the most trouble, letting a permanent tooth dry out, and trying to reimplant a baby tooth.

Chipped teeth, cracked teeth, and the gray area parents often miss

Not every dental emergency involves a tooth on the floor. In practice, chipped and cracked teeth are more common, and they create a lot of uncertainty because the child may look mostly fine. I have seen children finish a game, eat dinner, and only later complain that cold water “zings” one front tooth. A hairline crack or enamel fracture may be easy to miss.

When a baby tooth is chipped, the dentist is usually deciding between simple smoothing, a tooth-colored repair, or observation. Small chips are often manageable. Larger fractures that expose deeper layers can become painful and may risk infection. Some injured baby teeth darken over time, turning gray or brown weeks after the accident. That color change does not automatically mean disaster, but it is a sign the tooth needs follow-up. Sometimes the nerve recovers. Sometimes it does not.

With permanent teeth, even a modest chip deserves a closer look if the child reports sensitivity or if the break is near the nerve. Saving the fragment can help. Dentists can sometimes bond a broken piece back on, particularly in clean fractures of front teeth. That is one of those small details that can matter more than people expect.

Cracks are trickier than chips because they may not be visible without good lighting and examination. A child who avoids biting on one side, says the tooth hurts when releasing pressure, or suddenly dislikes cold drinks may have a crack that needs prompt assessment. Trauma can also damage the tooth root or the surrounding bone, injuries that do not show up clearly to the naked eye.

A tooth pushed out of place is often more urgent than it looks

Displacement injuries are common in children. A tooth may be shoved backward, forward, sideways, or upward. Parents often describe it as “crooked after the fall” or “it looks longer than the other one.” This is not something to watch casually at home.

Baby teeth that are displaced can injure soft tissue or affect the erupting permanent tooth, especially if the root has moved in an unfavorable direction. Some will reposition naturally. Others need intervention. The important part is timely evaluation, usually the same day or within 24 hours depending on severity and the child’s comfort.

Permanent teeth that are displaced are time-sensitive because repositioning and splinting may improve long-term outcomes. Even when the tooth looks only slightly off, the supporting ligament and surrounding bone may be significantly injured. If the child’s bite feels wrong, trust that complaint. Children often describe it very accurately even if they cannot explain it in dental terms.

Pain, swelling, and bleeding: what is normal and what is not

A certain amount of bleeding from the gums or socket is expected after trauma. Oozing for a while can be normal. So can mild swelling of the lip or gum. Pain that improves with ice, rest, and age-appropriate pain relief is reassuring, though it still may need dental follow-up.

What raises concern is bleeding that does not ease with pressure, rapidly increasing swelling, a fever Dental Emergency later on, pus, foul odor, or pain that worsens rather than settles. Another red flag is numbness of the lip or chin, which can suggest deeper injury. Difficulty opening the mouth, speaking clearly, or chewing may point to a jaw issue rather than an isolated tooth problem.

Young children sometimes will not tell you they hurt. Instead, they stop eating crunchy foods, drool more, wake at night, or become irritable when brushing. After a mouth injury, behavioral changes are worth noticing.

The mouth is not the only concern

Any significant blow to the mouth can involve more than the teeth. Lips often split against the front teeth. Tongues can be bitten badly enough to need medical attention. Small children sometimes drive a tooth edge through the lower lip, leaving a cut outside and a matching wound inside. Those can hide tooth fragments in the soft tissue.

It is also easy to focus on the tooth and miss the possibility of concussion or facial fracture. If the child lost consciousness, vomited, became unusually sleepy, complains of severe headache, or has obvious facial asymmetry, a medical evaluation comes first. Dentists deal with teeth. Head injuries and broken facial bones require a broader response.

A quick comparison that helps in the moment

The simplest rule is this: knocked-out baby teeth are not put back, knocked-out permanent teeth may need to go back immediately. Beyond that, there are a few practical differences worth remembering.

- Baby tooth knocked out: do not reimplant, control bleeding, call the dentist.
- Permanent tooth knocked out: time matters, keep it moist, seek immediate dental care.
- Baby tooth pushed into the gum or badly displaced: urgent dental assessment because of the permanent tooth underneath.
- Permanent tooth shifted or loose after trauma: urgent dental assessment to improve odds of saving it.
- Any tooth injury with head trauma, severe bleeding, or suspected jaw injury: medical care takes priority.

That short framework is often enough to help a parent act decisively instead of freezing.

What the dentist is looking for once you arrive

Parents sometimes expect the visit to center on the visible tooth alone. In reality, the exam is broader. The dentist will check tooth mobility, position, bite, gum injury, root development, and signs of damage to nearby teeth that may not yet hurt. Dental X-rays are often needed, not because every injury is severe, but because hidden changes matter.

In baby teeth, the dentist may be gauging whether the tooth can safely remain or whether removing it is better for the child and the future permanent tooth. In permanent teeth, decisions often involve splinting, pulp protection, bonding, root canal timing, and close follow-up over months. Trauma is not always a one-visit issue. Some teeth look fine initially and later show nerve changes or root resorption.

That delayed element is one reason follow-up is so important. A child may return in a few weeks for repeat evaluation even if the first visit seemed straightforward. The goal is to catch complications early, when there are still good options.

The emotional side matters too

Children remember dental trauma vividly. The blood, the noise of the fall, the crowd around them, the rush into an office, all of it can shape how they feel about dentists afterward. A calm adult response makes a real difference. So does careful language. Saying “the dentist is going to help your tooth feel safe again” lands better than “they might have to pull it.”

For school-age children, appearance can become a major concern within hours. A missing front permanent tooth at age eight or nine can feel devastating. Dentists know this, and many treatment plans balance biology with the child’s social world, speech, and confidence. That may mean temporary cosmetic options while healing unfolds.

Prevention is not glamorous, but it works

The injuries that bring children into emergency dental care are strikingly predictable. Bicycles without helmets, trampolines with multiple jumpers, scooters on steep driveways, and sports without mouthguards account for a large share. So do ordinary indoor falls involving coffee tables, bed frames, and bathroom fixtures.

A custom sports mouthguard is one of the best investments for a child in contact or collision sports, and even in basketball, skateboarding, or gymnastics, where accidental impacts happen more than people think. For toddlers,

some prevention is environmental: padded edges are less helpful than supervision around climbing hazards and hard surfaces.

None of this prevents every accident. Kids run, jump, trip, and collide. But prevention can reduce both how often injuries happen and how severe they are when they do.

The bottom line parents need to remember

When a child has a dental emergency, the first big decision is identifying whether the injured tooth is baby or permanent. That distinction changes the response. A knocked-out baby tooth should stay out. A knocked-out permanent tooth needs immediate attention and must be kept moist. Teeth that are pushed out of place, cracked deeply, or associated with bite changes deserve prompt evaluation no matter what type they are.

The best outcomes usually come from three things done well: staying calm, acting quickly, and avoiding well-meant mistakes. If you are ever unsure, call a dentist right away. In pediatric dental trauma, uncertainty is common, but delay is often the bigger problem. A short phone call can turn panic into a clear plan, and in the case of a permanent tooth, it can make the difference between losing a tooth and saving it.

Vitality Dental
Address: 1220 Coit Rd #106, Plano, TX 75075
Phone number: +19726454100

FAQ About Dental Emergency

What can the ER do for a tooth?

An emergency room (ER) can manage pain and treat severe infections with medication, but it cannot fix or pull a tooth.

What is considered a dental emergency?

A dental emergency is any oral health problem that involves severe pain, uncontrollable bleeding, or an infection that threatens your health or requires immediate care to save a tooth.

Is there a 24-hour dental service in Plano, TX?

There is no physical dental clinic in Plano, Texas, that stays open with walk-in staff 24 hours a day, but several offices offer 24/7 phone support, late-night hours, or same-day emergency care.